

## SWL in the treatment of matrix stones

.....

E. G. da Silva<sup>1</sup>, A. Figueiredo<sup>2</sup>, J. A. Sousa<sup>2</sup>, E. T. Morgado<sup>2</sup>

<sup>1</sup>Urologist, Head of the Endourology and ESWL Unit

<sup>2</sup>Urologist

Department of Urology and Transplantation  
University Hospital of Coimbra – Portugal

Correspondence: Edmiro Gomes da Silva  
Serviço de Urologia e Transplantação Renal – Unidade de Litotricia e Endourologia – Hospitais da Universidade de Coimbra  
Praceta Mota Pinto – 3000-075 Coimbra – Portugal  
Fax: +351 239 836 428 – E-mail: Litotricia@huc.min-saude.pt

### Summary

**Objective** – Given their mucoprotein structure, which promotes an acoustic impedance close to that of the water, matrix stones are not supposed to be fragmented by ESWL. The authors present four cases of matrix stones managed by ESWL.

**Patients and Methods** – Four patients with persistent urinary tract infections and clinical and radiological evidence of urinary stones, were treated by ESWL. One patient had a radiolucent staghorn calculi diagnosed as a uric stone, and the other three presented radiopac stones diagnosed as struvite stones.

**Results** – All patients expelled mucoproteic fragments after each ESWL session, allowing the diagnosis of matrix stones. Two patients were rendered free of stones, one was submitted to surgery with inferior polar nephrectomy, and the last one abandoned the treatment after having expelled several fragments of gelatinous material.

**Conclusions** – Given the unpredictable yet generally good results of ESWL, we believe that all renal stones should be given a chance of this modality, reserving more aggressive treatments for its failures.

**Key words:** Matrix Stones, ESWL and Matrix Stones.

### Resumo

**Objectivo:** os cálculos de matriz são constituídos por uma estrutura mucoproteica e como tal, com uma impedância acústica idêntica à da água. Assim, era presumível que não fossem destruídos pela Litotricia Extracorpórea. Os autores apresentam aqui

quatro casos de doentes com cálculos renais, tratados por LEOC, e que expulsaram fragmentos de cálculos moles.

**Doentes e Métodos:** quatro doentes, com infecções urinárias de repetição e sinais clínicos e radiológicos evidenciando a existência de cálculos renais, foram tratados por litotricia extracorpórea. Um doente tinha um cálculo coraliforme radiotransparente, diagnosticado como cálculo de ácido úrico. Os outros três tinham cálculos mistos, radiopacos e radiotransparentes, diagnosticados como cálculos de estruvite.

**Resultados:** após os tratamentos por LEOC, todos os doentes expeliram fragmentos mucoproteicos, o que permitiu concluir que se tratavam de quatro casos de Cálculos de Matriz. Dois doentes ficaram curados sem cálculos nem resíduos, um doente foi operado por pielolitotomia e nefrectomia polar inferior e finalmente um quarto doente, após expulsar fragmentos gelatinosos de Cálculos de Matriz, abandonou os tratamentos por razões desconhecidas.

**Conclusões:** dado que os resultados dos tratamentos por LEOC são, regra geral, imprevisíveis mas bons e inócuos numa elevada percentagem de casos, os autores acreditam que, na maioria das situações de litíase renal, deve ser sempre tentada a LEOC, reservando os tratamentos mais invasivos para os fracassos de litotricia extracorpórea.

## Introduction

Matrix stones are a rare form of renal stones made of mucoproteins. Their chemical composition is similar to that of the struvite matrix, and in almost all cases they are associated with infection by urea splitting bacteria. On 29 cases reviewed in 1980, all but one were associated with urinary infection<sup>1</sup>. It is not known why mineralization of matrix does not occur. The radiologic aspect of these stones depends on the degree of mineral incrustations, struvite and calcium fosfate in most cases. When the level of crystal incrustation is low, their radiolucency make them look on the intravenous pyelography (IVP) as an uric acid stone. On the other hand, they may seem like mixed stones of uric acid and struvite or calcium oxalate if the crystal incrustation is high and heterogeneous. In most cases, diagnosis is only made by direct examination of a fragment, being it obtained surgically or eliminated in the urine. The optimal treatment for matrix stones is not established. The authors present four cases of matrix stones treated by extracorporeal shock wave lithotripsy (SWL).

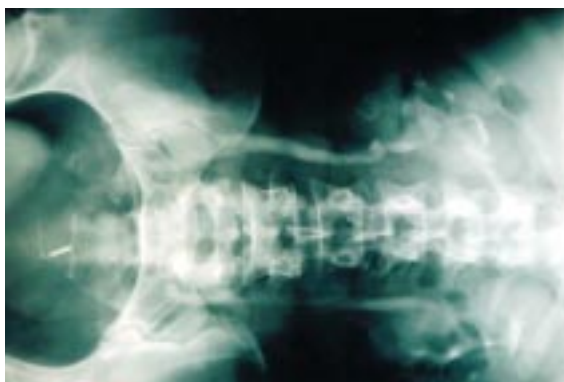## Patients and Methods

All patients -four females- presented with a history of recurrent urinary tract infections lasting from five to

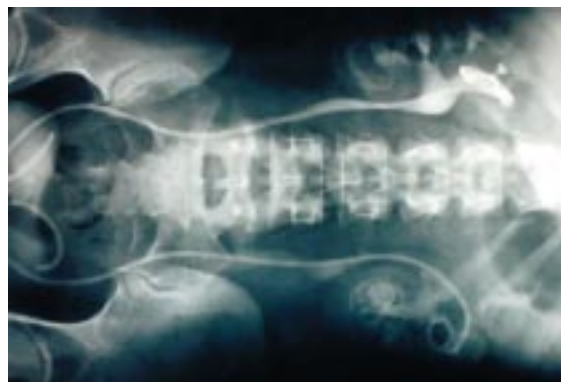
eight years. Urine cultures were positive for *Proteus mirabilis* in two patients, *Klebsiella* in one, and *Proteus mirabilis* + *Echerichia coli* in the fourth patient. Patients were submitted to IVP, that revealed different patterns. One case looked like a urate staghorn calculi, being radiolucent with several fine radiopac incrustations (fig. 1). Another showed three faintly radiopac calculi, one at the left ureteropyelic junction, one at the right pelvic ureter and another occupying the pelvis and lower pole of the kidney.(fig. 2). In the third patient it was detectable a heterogeneous radiopac mass occupying the lower pole and part of the pelvis of the kidney and the last one had fine radiolucent an radiopac spots in almost all calyces suggesting infeccious calyceal stones (fig. 3). A double J stent was introduced in all patients before starting SWL and antibacterial drugs were given throughout the treatment and for several months thereafter. All patients were treated with piezoelectric lithotriptors, an EDAP LT01 at a frequency rate of 2.5 shots/second in two cases, and an EDAP LT02 at a frequency rate of 2 shots/second in the other two.

## Results

SWL sessions were well tolerated, and ultrasound localization of the stone was easily accomplished in all cases. Several fragments of matrix started to be



**Fig. 1** – Staghorn radiolucent matrix calculi (easily detected by ultrasonography due to their fine struvite incrustations).

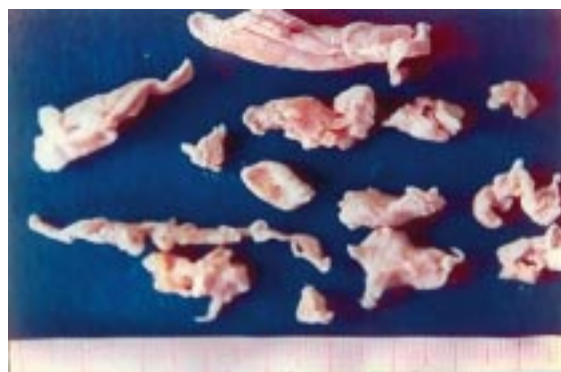

**Fig. 2** – IVP from the failed case. Despite the elimination of matrix fragments after the two first sessions, the patient was submitted to a Pielolithotomy and lower polar nephrectomy.

eliminated in the urine after every first session. Two patients were rendered completely free of stones on ultrasound and IVP controls after five and eight sessions. One of these expelled large matrix fragments (fig. 4). Another patient had a poor response after six ESWL sessions and was submitted to pyelolithotomy and lower pole nephrectomy. The stone had a plaster look and was incrustated by particles of struvite. The fourth patient abandoned the treatment after six sessions, having already expelled many gelatinous fragments of matrix. The three patients under our control are free of urinary tract infections..

## Discussion

In the past, almost all matrix stones were treated by open surgery.<sup>2,3</sup> With the development of endourology, percutaneous nephrolithotomy and ureteroscopy became the leading treatment options.<sup>4, 5, 6, 7</sup> However, the scant literature on matrix stones does not allow to consider any treatment as Standard therapy. To the best of our knowledge, there is only one paper in the literature where ESWL was used in the treatment of matrix stones.<sup>8</sup> The main reason may reside in the theoretical incapacity of ESWL to destroy mucoprotein, given its acoustic impedance close to that of the water. Nevertheless, in all our four cases, fragments of matrix stones were expelled after every ESWL session. We believe that ESWL promotes the disruption of the mucoprotein fibrillar and laminar structure links by the explosive effect of cavitation.<sup>9,10</sup> This promotes the detachment of the stones from the renal calices and pelvis, allowing the elimination of



**Fig. 3** – Fragments expelled by the patient with the radiolucent staghorn calculi.

voluminous fragments (fig. 2). Whether this applies to all matrix stones needs to be confirmed by wider experience. However, it is our conviction from this cases, that the more gelatinous the fragments are, more easily they are detached and expelled from the kidney. In our department, all renal stones are given a chance for ESWL treatment, whichever their size or composition, given its higher safety than any other option, and unpredictable yet generally good efficacy even in large calculi.<sup>11</sup>

## Conclusion

SWL promoted the elimination of mucoprotein fragments in all cases in which it was applied. Despite our one unsuccessful case, we think that ESWL should be considered the first treatment option for matrix stones, and only after its failure other treatment options should be tried.

## References

1. Silva EG, Sousa JA, Madeira AS: A case of matrix stones. *O Medico* 1980; 1484: 229-36
2. Allen TD, Spence HM: Matrix stones. *J.Urol* 1966; 95: 284-5.
3. Cubilana LP, Pastor GS, Villaplana GH, Rosino GH, Egea LA, Falgas GS: Litiasis blandas. A proposito de um caso de litiasis coraliforme. *Act Urol Esp* 1994; 18: 608-11.
4. Cadeddu JA, Jarret T. Use of a nasogastric tube to evacuate stone debris after ureteroscopic holmium lithotripsy: *Urology* 1998; 52: 882-4
5. Anjum MI, Palmer JH: Stone matrix clearance from the pelvicalyceal system using a bottle-brush. *Brit J Urol* 1996; 78: 460-3
6. Royola CT, Sanz CR, Vela LR, Bengoecha JM, Sanz LAR: Matrix stones. *Arch Esp Urol* 1993; 46: 329-31
7. Arias JG, Catalina AJ, Gonzalez JG, Malfaz C: Multiple matrix lithiasis: integral endourological treatment. *Arch Esp Urol* 1995; 48: 405-8
8. Silva EG, Figueiredo A, Sousa JA, Morgado ET: Matrix Staghorn Calculus Treated by Extracorporeal Shock Wave Lithotripsy. Hans-Goran Tiselius. *Renal Stones – aspects on their formation, removal and prevention. Proc. of Sixth European Symp. on Urol. Stockholm, June 8-10, 1995.*
9. Koide T, Miyagawa M, Kinoshita K: Matrix stones. *J Urol* 1977; 117: 786-7.
10. Silva EG, Carvalho, RG: Physical effects of shock waves on the kidney. A comentary based on several experiments. *Arch Esp Urol* 1992; 45: 91-4.
11. Silva EG, Figueiredo A, Sousa, JA, Rabaça C, Morgado ET: Ambulatory ESWL Monotherapy in Staghorn Calculi. *Brazilian J. Urol.* 2000;26(6)571-578.