

Casos Clínicos

Gangrena de Fournier numa Mulher

António Murinello¹, A Manuel Figueiredo¹, Mónica Athayde²,
Bruno Grima³, Vasco Ribeiro⁴, Sofia Lourenço³,
Cândida Fernandes⁵, Marta Goja¹, J Figueira Coelho²

1 - Serviço de Medicina Interna

2 - Serviço de Radiologia

3 - Serviço de Urgência

4 - Serviço de Cirurgia

5 - Serviço de Dermatologia

Hospital de Curry Cabral

Correspondência: Antonio Murinello – Av.^a Eng.^o Ant.^o Azevedo Coutinho, Lt 8 r/c - Dto.
– 2750-644 CASCAIS – E-mail: amurinello@yahoo.com – amurinello@gmail.com

Resumo

A fasceíte necrotizante dos tecidos infra-diafragmáticos (gangrena de Fournier) é uma grave infecção sinérgica por agentes aeróbicos/anaeróbicos, com uma evolução clínica súbita e rápida de gangrena da fascia e sepsis generalizada, associada a elevada mortalidade. Trata-se de uma emergência médico-cirúrgica necessitando de tratamento intensivo englobando a correcção das anomalias hemodinâmicas, hidroelectrolíticas e metabólicas, antibioterapia dupla/tripla de largo espectro por via endovenosa, desbridamento cirúrgico agressivo do tecido necrótico infectado e correcção da determinante etiológica da gangrena. É frequente encontrar como factores de risco a diabetes mellitus, doença crónica hepática, doenças malignas, doenças imunológicas congénitas ou adquiridas, tratamento com fármacos imuno-supressores, alcoolismo crónico e má nutrição. As fontes infecciosas originais conducentes a uma gangrena de Fournier são geralmente abscessos da área peri-anal ou processos infecciosos genitourrológicos. Embora a gangrena de Fournier seja muito menos frequente na mulher que no homem, é importante pensar nesse diagnóstico, de forma a proporcionar às doentes a possibilidade de tratamento com sucesso. Descreve-se o caso de uma gangrena de Fournier, determinada por um abscesso da fossa ísquio-rectal, numa mulher diabética e em tratamento de um *penfigus vulgaris* com fármacos imuno-supressores, com evolução fatal, possivelmente em resultado de diagnóstico e tratamento tardios.

Palavras chave: Gangrena de Fournier, Fasceíte necrotizante, Abscesso ísquio-rectal, Diabetes mellitus

Abstract

Necrotizing fasciitis of the infra-diaphragmatic tissues (Fournier's gangrene) is an acute, highly fatal type of infection wherein there is a rapidly spreading fascial gangrene and systemic sepsis. It is a medical-surgical emergency requiring intensive care for correction of associated hemodynamic, fluid and electrolyte, as well as metabolic

abnormalities. It also requires broad spectrum intravenous double/triple antibiotic therapy, and aggressive surgical debridement of infected necrotic tissue. Diabetes mellitus, chronic liver disease, malignancy, congenital or acquired immune systemic disorders, and the use of immunosuppressive drugs, chronic alcoholism and malnutrition, are common general risk factors. The usual sources of the infection leading to Fournier's gangrene are abscesses in the peri-anal area and chronic genitor-urinary problems. Although Fournier's gangrene is less frequently seen in female than in male patients, it is still important to be aware early on of the possibility so that these patients may benefit from early treatment. We are presenting the case of a diabetic female currently on immunosuppressive drug therapy for *pemphigus vulgaris*, who developed an ischio-rectal abscess with a dismal outcome because of a late diagnosis and treatment.

Key words: Fournier's gangrene, Necrotizing fasciitis, Ischio-rectal abscess, Diabetes mellitus

Introduction

Fournier's gangrene is a necrotizing fasciitis of the infradiaphragmatic soft tissues, usually affecting the male genitals and perineum. Although the disease was first described by Baurienne in 1764, it was named after a French venereologist, Jean-Alfred Fournier (March 12, 1832 – December 23, 1914), who treated five patients he presented in his clinical lectures in 1883 (1). JA Fournier's main contribution to medical science was the study of congenital syphilis being the cause of degenerative diseases. He also founded an organization called the *Société Française de Prophylaxie Sanitaire et Morale*. The most historically prominent sufferers from Fournier gangrene may have been Herod the Great, the Roman emperor Galerius, and the Puerto Rican abolitionist and pro-independence leader Segundo Ruiz Belvis (1).

In the majority of cases Fournier's gangrene is a synergistic aerobic-and anaerobic infection that has a sudden and unpredictable clinical course, rapidly spreading from its point of origin leading to fulminant increasing fascial gangrene and systemic sepsis (2). Fournier's gangrene is a medical-surgical emergency, generally requiring intensive care procedures of hemodynamic stabilization and hydro-electrolyte and metabolic corrective measures, intravenous antibiotics with double/triple associations, surgical debridement of necrotic infected tissue and repeated surgical drainage (3). Hyperbaric oxygen therapy is sometimes useful, because it has anaerobic bactericidal properties (4). Despite early treatment, the mortality rate is around 30% to 40% (5,6), and it even

higher if sepsis is already present at the time of diagnosis (5). More often, significant co-morbid factors are also present and greatly contribute to the high mortality rate of this disease entity.

Men are ten times more likely to develop Fournier's gangrene than are females (6,7,8,9), perhaps due to the easier drainage of the female perineum via the vaginal route, which may hinder (10) the development of the disease. Clinical situations such as bacterial abscesses in the vaginal area (abscesses of Bartholin gland and of the vulva), episiotomy, septic abortions, and hysterectomy may predispose or cause Fournier's gangrene (7,9). General risk factors common to both sexes are old age, diabetes mellitus, alcoholism and chronic liver disease (11), morbid obesity, leukemia, immune system disorders (HIV infection, Crohn's disease), intravenous drug use, perineal wounds, local surgical procedures, immunosuppressive drugs, local radiation therapy, chronic renal insufficiency, poor perineal hygiene (12). Insect bites, burns, trauma, and circumcision have been reported as causes of rarely seen Fournier's gangrene in pediatric patients (13).

In the era of modern radiographic investigation the cause of Fournier's gangrene is usually identified, with only 10% of cases being idiopathic (14). Local infection adjacent to a point of entry, including abscesses (more commonly in the perianal, perirectal, and ischio-rectal regions), anal fissures, and colonic perforations, are the most common etiologies for the development of the gangrene. Rectal carcinoma and diverticulitis are also possible causes (15). The urologic sources of Fournier gangrene included urethral strictures,

chronic urinary tract infections, neurogenic bladder, recent instrumentation, and epididymitis (13).

The commonest source of sepsis in Fournier's gangrene is the anorectum. The condition is more prevalent in the older age group (above 50 years). Ischiorectal fossa abscesses, perineal abscesses and inter-sphincteric abscesses have all been described as sources of infection (16). Ischiorectal fossa abscesses are rarely life threatening although they can have a fatal outcome. In diabetics the gangrene usually has a more fulminant course because of the inherent neutrophil dysfunction with decreased phagocytic and intra-cellular bactericidal activity (16). It is important to proceed to emergency drainage and adequate debridement with deroofting of the abscess cavity by an experienced surgeon.

In a paper by Sorensen MD et al (9) the authors stated that, in a review of hospital based database available in the United States in 2001 and in 2004, cases of Fournier's gangrene represented only 0.02% of hospital admissions. The occurrence of Fournier's gangrene in women is probably underreported and may go unrecognized by non experienced clinicians. The authors describe a case of Fournier gangrene due to an ischiorectal abscess in a female patient with uncontrolled diabetes mellitus and concurrently taking immunosuppressant drugs for treatment of *Pemphigus vulgaris*, who was diagnosed very late, thereby substantially curtailing the possibility of a more favorable prognosis.

Clinical Report

A 84-year-old Gypsy was admitted from the Emergency Unit to our Internal Medicine Unit at the night of 09APR20, with a diagnoses of uncompensated diabetes mellitus and sepsis. She was diagnosed with diabetes mellitus 21 months ago (JUNE07) and was taking glicazide until JAN09, when she was admitted in the Dermatology Unit of our hospital due to oral and disseminated cutaneous lesions diagnosed as *Pemphigus vulgaris*, through skin biopsy (deposits of IgG at the epidermal intercellular cement) and antibodies to desmoglein 1: 64.70 UI/mL (N <20.00) and desmoglein 3: 170.40 UI/mL (N <20.00). She was treated with methylprednisolone (60 mg daily) and azathioprine (100 mg daily) with resolution of the

lesions. Due to the presence of a concomitant anemia (Hb 10.8 g/dL) a colonoscopy was performed, but there was no pathologic lesion found. On discharge she prescribed with a tapering dose schedule of a corticosteroid plus azathioprine 50 mg daily, metformin and natglinide for control of her diabetes. Because of financial constraints, the patient was lost to follow-up and was erratic in taking her medications.

A week before admission her family revealed that the patient had diarrhea and persistently uncontrolled blood sugar. Four days previous to admission the patient came to the Emergency Ward where a diagnosis of a left perineum abscess and uncontrolled diabetes (capillary blood glucose of 500 mg/dL). A surgical referral was not considered because they thought the existing two ulcerated lesions were already draining adequately. The patient was sent home with the following oral medications: ciprofloxacin, metronidazole and ibuprofen. Her clinical situation deteriorated and she came again to the Emergency Ward at the day of admission in a confusional state, with dehydration due to diabetic ketoacidosis (glycaemia 625 mg/dL; blood gases: pH 7.333; SBEC -9.2 mmol/L; HCO₃⁻ 15.0 mmol/L; pCO₂ mmHg; pO₂ 82.1 mmHg; sO₂ 95.4%). Other pertinent LAB tests revealed: CBC: Hb = 10.3 g/dL; MCV 85.6 fl; MCH 28.4 pg; MCHC 33.2 g Hb/dL ; wbc ct = 10.9x10⁹/L; platelet ct = 296x10⁹/L; PCR 22.8 mg/dL . Blood chemistry: urea 126 mg/dL; creatinine 1.4 mg/dL (creatinine clearance calculated as 28 ml/min.); Electrolytes (sodium 127 mEq/L; potassium 6.4 mEq/L; chloride 87 mEq/L); serum albumin 2.19 g/dL; normal liver function tests and CPK. Urinary sediment was sterile. EKG and x-Ray were both normal. A urinary catheter was inserted for urinary diversion. Despite the worsening clinical condition of the patient, there was still no surgical intervention done and the patient was admitted to our Unit of Internal Medicine on the night of day 09APR20, and was started on (regular) insulin drip, intravenous fluids and intravenous piperacillin/tazobactam plus metronidazole.

We saw the patient for the first time in the morning of 09APR21, disoriented, dehydrated, and unable to give a reliable medical history. Her vital signs were: T 37.3° C, BP 102/57 mmHg, HR 96bpm, RR 24 pm. There was oral thrush on the tongue as well as dental caries. Cardiopulmonary

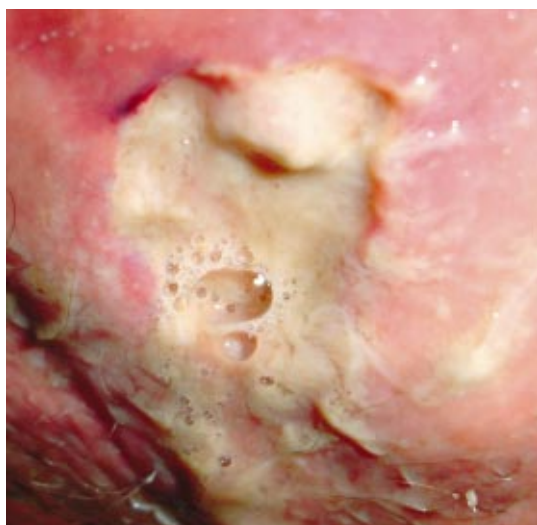


Fig. 1 – Purulent deep ulcer of the per-ianal area.

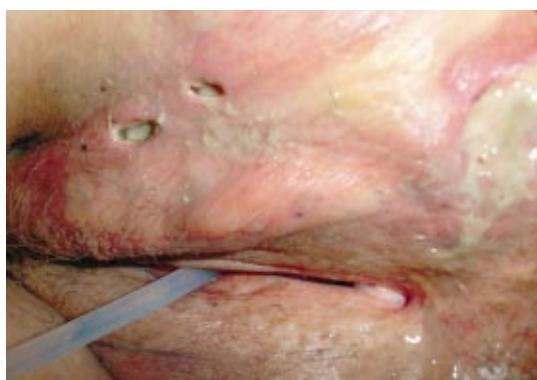

Fig. 2 – Two ulcers of the vulva with purulent exudate.

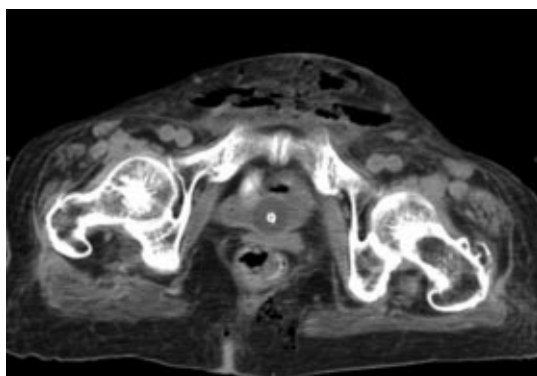


Fig. 3 – Abdominal-pelvic CT scan: revealing a posterior peri-anal fluid collection, in connection with peri-anal fistula.

findings were normal. Abdominal palpation was slight tenderness on the lower quadrants. Negative for crepitus. There was +2 bipedal edema. The left peri-anal area was erythematous and tender with the presence of a deep ulcer measuring 1.5 cm oozing with fetid purulent exudate. There were

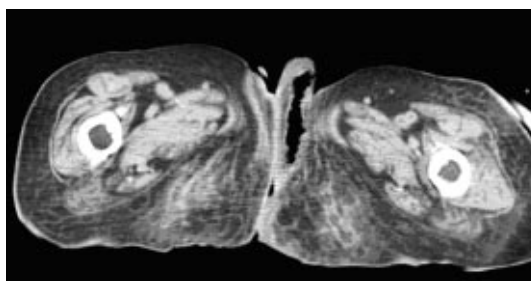


Fig. 4 – Abdominal-pelvic CT scan: showing gas in the vulva.

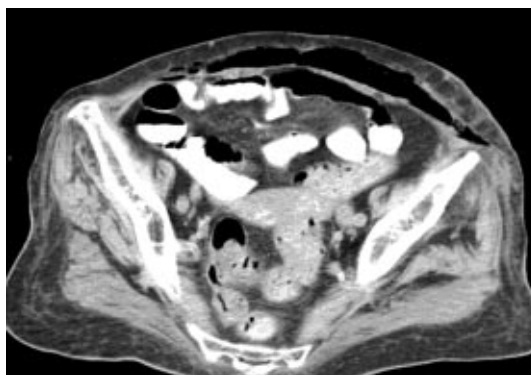


Fig. 5 – Abdominal-pelvic CT scan: with evidence of subcutaneous emphysema of the anterior abdominal wall.

two smaller ulcers at the vulva draining with pus. No etiologic microbial agent (s) was (were) not identified (Figs. 1, 2). An emergency contrast-enhanced CT scan of the abdomen and pelvis was done (16.00 h), which revealed findings in favor of necrotizing fasciitis of the perineum (Fournier's gangrene) namely: (a) a posterior peri-anal fluid collection with a diameter of 26 mm in connection with peri-anal fistula (Fig. 3); (b) tubular gas images at the peri-anal area and in the and vulva (Fig. 4); (c) extensive subcutaneous emphysema involving the anterior abdominal wall until the umbilicus (Fig. 5) associated with subcutaneous fat edema. The patient was immediately transferred (18.00 hours) to the Emergency Ward for intensive multidisciplinary care (18.00h).

At the Emergency Ward the patient was dehydrated, afebrile, and hypotensive (BP 94/54 mmHg). LAB tests done at 18.00 hours of day 21APR09 showed: CBC: Hb 9.4 g/dL; WBC count $8.4 \times 10^9/L$; platelet ct $210 \times 10^9/L$. Coagulation tests were normal. Blood chemistry: blood sugar 264 mg/dL; ketonemia 6.3 mg/dL; ketonuria 5 mg/dL; plasmatic urea 71 mg/dL; creatinine 0.8 mg/dl; electrolytes (sodium 130 mEq/l; potassium 3.8 mEq/L; chloride 95 mEq/L. Arterial blood gases: (pH 7.453; SBEC -

2.2; mmol/L; HCO₃⁻ 22.7 mmol/L; pCO₂ 30.6 mmHg; pO₂ 44.4 mmHg; sO_{2a} 84.6%). The results of several blood cultures performed during two days were later known to be negative. The Insulin drip, intravenous fluid hydration and the same antibiotics were continued.

The patient was examined by a surgeon at 23.00 h, it was decided to surgically intervene but unfortunately it was possible to perform surgery only at 3.30 am of day 22APR09, when crepitus due to subcutaneous emphysema was already conspicuous. After a transfusion of one unit of packed red cell, surgical incisions of the skin and subcutaneous tissue of the lower left abdomen and of the perineal areas were performed, with debridement of all necrotic tissue, which was also manifested as a horse-shoe abscess from the left to the right gluteal regions and of the left vulvar region, communicating with the abdominal wall in front of the pubic bones. Profuse cleaning of all surgical area was realized and continuous drainage of the affected areas was maintained. Meanwhile, as more necrotic tissue developed and as the patient's clinical situation deteriorated progressively, additional debridement of the newly formed necrotic tissue was performed during the night of day 22APR09. The patient was also transfused with one unit packed red cells. But despite all these medical and surgical measures to correct metabolic derangements and the ongoing infection, the patient went into multiorgan failure and died 22APR09. Autopsy was not anymore requested.

Discussion

Necrotizing fasciitis refers to necrotizing soft-tissue infection affecting any part of the body and spreading along fascial planes, involving superficial fascia, subcutaneous fat, nerves, arteries, veins, and the deep fascia. The earliest report of probable necrotizing fasciitis dates back to Hippocrates, and in modern times it was described by Joseph Jones, a confederate army surgeon, in 1871, during the US Civil War, as hospital gangrene (2). The term necrotizing fasciitis was first used in 1952 by Wilson, referring to the most consistent feature of the infection, fascial necrosis (17).

Necrotizing fasciitis may be caused by a single organism such as *Streptococcus pyogenes* or *Vibrio vulnificus* or more frequently mixed infections by

aerobic and anaerobic bacteria. The diagnosis of necrotizing fasciitis depends on a high index of suspicion. The initial findings are localized pain and minimal swelling, often with no visible trauma or discoloration of the skin. Deep tissue sites, especially surgical wounds and perirectal areas, have the fewest signs and symptoms. As the infection spreads along fascial planes, dermal induration and erythema become evident. Overlying skin is left intact initially, but as the process extends, there is thrombosis of perforating vessels to the skin, which turns black (dermal gangrene) then sloughs off. Bacteremia is rare but uncontrolled infection progresses to septicemia causing patient's death (18). The precise mechanism resulting in the fascial necrosis is not known, the cause thought to be the action of bacterial enzymes, including lipases and hyaluronidase, which degrade fat and fascia. On experienced hands, frozen section tissue biopsy could provide a reliable diagnosis of necrotizing fasciitis, but the diagnosis is essentially clinical and radiographic (17).

Today, Fournier's gangrene is recognized as site-specific appearance of necrotizing fasciitis. Necrotizing fasciitis of the abdominal wall and of the perineum, peri-genital and peri-anal region have so much in common that from a diagnostic point of view they are considered as a clinical entity. As etiological agents, most series of Fournier gangrene refer to synergistic microbiology involving common perineal, urologic and coloproctologic aerobic and anaerobic microflora (*Escherichia coli*, *Proteus spp.*, *Streptococcus group A*, *Pseudomonas spp.*, *Klebsiella pneumoniae*, *Staphylococcus spp.*, *Bacteroides spp.*, *Clostridium perfringens*, and *fungi*) (19).

Although it is accepted today that some cases of Fournier's gangrene can initially have an insidious onset, usually it courses very fast causing sometimes in a few hours, an extensive necrosis and soft tissue loss, with the possibility of extension of the infectious process from the perineum to the fascia of the anterior and posterior abdominal wall, and even to the thorax, buttocks, thighs and arms (19). In some patients the absence of any obvious local signs that usually accompany the more serious symptoms of fever, shivers, hypotension, anxiety and confusion generally seen in Fournier's gangrene may mislead one to think of other possible explanations for these symptoms and may delay diagnosis (19).

It is important to diagnose Fournier's gangrene early because performing immediate aggressive surgical debridement, as well as starting patients on double or triple broad spectrum antibiotic therapy and correction of metabolic alterations, can be life-saving. The onset of symptoms usually occurs over a period of 2-7 days, and the most common presenting symptoms include swelling, pain, hyperemia, pruritus, crepitus, and fever. A foul-smelling discharge from necrotic areas is also frequent. Crepitus is detected in 19%-64% of patients. Soft-tissue gas may be present prior to the detection of clinical crepitus, being most easily visualized by CT scan (13). Air in the soft tissues (emphysema) means insoluble gas produced by anaerobic gas-forming bacteria and consists primarily of nitrogen, hydrogen, nitrous oxide, and hydrogen sulfide. CT scan features of Fournier's gangrene also include asymmetrical fascial thickening and inflammation, any coexisting fluid collection or abscess, and fat stranding around the involved structures (13). The underlying cause of Fournier gangrene, such as peri-anal abscess, a fistulous tract, an intra-abdominal or retroperitoneal infectious process, or a colonic perforation, may also be demonstrated at CT scan. The extent of fascial thickening and fat stranding seen at CT scan has been found to correlate well with the affected tissue at surgery (8).

As it was already mentioned, early diagnosis is the key to survival, and so that prompt aggressive treatment of Fournier's gangrene and the underlying conditions is essential (6,20). Double or triple antibiotic therapy must be started as soon as possible, although they alone do not reduce mortality. The culture and Gram stain should guide the antibiotic therapy, but while waiting for the results broad-spectrum antibiotics aimed at *Streptococci*, anaerobes, enteric gram-negative organisms, and *Staphylococci* should be given. Frequently used agents are third generation cephalosporins, aminoglycosides, β -lactamase inhibitor combinations plus clindamycin or metronidazole. Supportive care is also very important, including correction of fluid and electrolyte abnormalities and control of blood sugar, and providing nutritional support (3,11). Assuming that inflammatory mediators are essential in the physiopathology of Fournier's syndrome, some authors advised the utilization of very high doses of corticosteroids, referring good therapeutic results (19).

There is a worldwide consensus that, as soon as possible, radical excision of the gangrenous tissue, accompanied by intensive care measures, is essential for eventual survival of the patients. Due to the infiltrating nature of the necrotizing fasciitis, most patients need repeated debridements to remove any source of remaining infection, usually during the stay at the intensive care unit. Urine deviation via suprapubic catheter is frequently needed, whereas fecal diverting via colostomy is probably indicated in cases of severe perianal involvement (2,16) (infection of the sphincter, demonstrable rectal perforation, large rectal wound, or in cases of immune-compromised patient). Reconstructive correction of functional and cosmetic defects can be done afterwards (2).

Hyperbaric oxygen therapy (HBO) and honey are treatment modalities yet to be universally adopted. HBO has several useful properties: (a) eutrophic activity; (b) bactericidal effect on anaerobic microorganisms due to increased tissue oxygen tension; (c) stimulation of phagocytosis; (d) increases the efficacy of certain antibiotics (3). However, HBO does not seem to have an advantage in terms of improving morbidity and mortality rates (2). Moreover HBO is not available everywhere, and it should be reserved for the rare cases of proven isolated *Clostridia* infection (2).

A very interesting case from Nigeria is that of Efem SE (21), who managed conservatively twenty consecutive cases of Fournier's gangrene, with oral systemic antibiotics (amoxicillin / clavulanic acid and metronidazole), and daily topical application of unprocessed honey to the gangrenous scrotum. Even though the average duration of hospitalization was slightly longer than a group treated by conventional methods, the author finds no death in the group treated with honey, and the need for anesthesia and extensive surgical operation was avoided. Honey appears to help to remove more quickly the slough and necrotic tissue, through its biochemical and enzymatic debriding action. Even though the patients in this series had not so serious co-morbidity as in other series, the results may open our mind to a revolutionary treatment for this dreadful disease. Subrahmanyam M et al (22) also obtained beneficial results with honey dressing in the treatment of 30 male patients with Fournier gangrene, eight of whom with diabetes mellitus, after a basic treat-

ment of prompt excision of all non-viable tissue, control or abolition of factors which may cause infection, and initiation of appropriate antibiotics.

Honey is a mixture of sugars prepared by the bees from natural sugar solutions called the nectar, obtained from flowers. By inverting the sucrose in the nectar, the bee increases the attainable density of the final product, thus raising the efficiency of the process in terms of caloric density. The higher osmotic pressure thus obtained prevents the growth of bacteria and fungi. "Ayurvedica" Hindu medicine advises honey for the treatment of various ailments, being useful in controlling the infection of wounds and burns. Honey is produced from many floral sources and its anti-bacterial activity varies, which explains why there is so much of variation in *in-vitro* of the sensitivity of wound-infecting bacteria to honey. Honey was found to inhibit bacterial growth which is found to be due to its low pH, high viscosity, the hygroscopic effect and presence of the enzyme glucose oxydase that produces low levels of hydrogen peroxidase (i.e. inhibine) and anti-oxidants. Honey may also work by stimulating the activity of the immune system and by releasing the following: cytokines: TNF-1, IL-1, and IL-6, which are intermediates in the immune response (23). Patients treated with honey showed faster appearance of healthy granulation tissue (22). There is some debate whether honey should be sterilized by gamma irradiation before use, because the hypothetical risk of *Clostridial* spores contamination of honey, but many authors have used unprocessed honey in several clinical trials, not referring *Clostridial* infection or any other complication. Honey was found to be sterile and can be safely used (22). However, dressings with honey treated by gamma-radiation can be utilized, without loss of the antibacterial activity of honey. Honey is cheap, cost-effective and easily available. The authors conclude that efficacy and safe use of honey needs to be confirmed by multicenter randomized clinical trials before its routine use can be recommended as an adjunct to standard treatments used by most clinicians.

The causes of death include severe sepsis, acute consumptive coagulopathy, acute renal or respiratory failures, diabetic ketoacidosis and multiple organ failure. Generally, patients with lethal outcome, have the highest degree of co-mor-

bidity preoperatively (2). In Fournier's gangrene sepsis originating from anorectal sources is usually associated with higher mortality than those due to urological causes (2).

Although early aggressive surgical treatment is considered by most authors to be a very important factor in determining reduction of mortality rate, the physiological state of the patient is considered the most important factor in determining prognosis. Since escalation of abnormalities of homeostasis is known to be associated with a worse prognosis, attempts to better define the prognosis have been done with utilization of Fournier's gangrene severity scores (24,25,26). These scores are obtained by considering several data related to sepsis: heart rate, respiratory rate, serum creatinine, serum bicarbonate, serum lactate, serum calcium, serum albumin, serum lactic dehydrogenase, hematocrit, WBC and platelet counts. In general, a Fournier's gangrene severity index score threshold above 9 means a much higher mortality rate (24).

In the case of our patient, severe pathophysiological determinants, uncontrolled diabetes mellitus, immunosuppressive therapy, late diagnosis with subsequent delay in treatment all contributed to the dismal outcome of the patient.

Bibliography

1. http://en.wikipedia.org/wiki/Jean-Alfred_Fournier
2. Ecker K-W, Baars A, Topfer J, Frank J. Necrotizing fasciitis of the perineum and the abdominal wall-surgical approach. *Europ J Trauma Emerg Surg* 2008; 34: 219-28
3. Benizri E, Fabiani P, Migliori G, Chevallier D, Peyrotter A, Raucoules M, et al. Gangrene of the perineum. *Urology* 1996; 47: 935-939
4. Zamboni WA, Riseman JA, Kucan GO. Management of Fournier's gangrene and the role of hyperbaric oxygen. *J Hyperbaric Med* 1990; 5: 177-186
5. Yanar H, Taviloglu K, Ertekin C, Guloglu R, Zorba U, Cahioglu, et al. Fournier's gangrene: risk factors and strategies of management. *World J Surg* 2006; 30: 1750-1754
6. Eke N – Fournier's gangrene: a review of 1726 cases. *Br J Surg* 2000; 87: 718-728
7. Atakan IH, Kaplan M, Kaya E, Aktöz T, Inci O. A life-threatening infection: Fournier's gangrene. *Int Urol Nephrol* 2002; 34: 387-392
8. Grayson DE, Abbott RM, Levy AD, Sherman PM. Emphysematous infections of the abdomen and pelvis: a pictorial review. *Radiographics* 2002; 22: 543-561

9. Sorensen MD; Krieger JN, Rivara FP, Broghammer JA, Klein MB, Mack CD, et al. Fournier's gangrene: Population based epidemiology and outcomes. *J Urology* 2009; 181: 2120-2126
10. Gurdal M, Yucebas E, Tekin A, Beysel M, Aslan R, Sengor F. Predisposing factors and treatment outcome in Fournier's gangrene. *Urol Int* 2003; 70: 286-290
11. Kuo CF, Wang WS, Lee CM, Lin CP, Tseng HK. Fournier's gangrene: ten-year experience in a medical center in northern Taiwan. *J Microbiol Immunol Infect* 2007; 40: 500-506
12. Korkut M, Iço G, Dayangaç M, Akgun E, Yeniay L, Erdogan O, et al. Outcome analysis in patients with Fournier's gangrene: a report of 45 cases. *Dis Colon Rectum* 2003; 46: 649-652
13. Levenson RB, Singh AK, Novelline RA. Fournier gangrene: Role of imaging. *Radiographics* 2008; 28: 519-528
14. Sapioleas M, Stamatakos M, Monzopoulos G, Diab A, Kontoglou K, Papachristodoulou A. Fournier's gangrene: exists and it is still lethal. *Int Urol Nephrol* 2006; 38: 653-657
15. Ash L, Hale J. CT findings in perforated rectal carcinoma presenting as Fournier's gangrene in the Emergency Department. *Emerg Radiol* 2005; 11: 295-297
16. Moorthy K, Rao PP, Supe AN. Necrotizing perineal infection: a fatal outcome of ischiorectal fossa abscesses. *JR Coll Surg Edimb* 2000; 45: 281-284
17. Feely EA. Necrotizing fasciitis: diagnostic modalities. http://intmedweb.wpubmc.edu/grand_rounds/1998/necrotizing_fasciitis.html
18. Ahrenholz DH. Necrotizing soft tissue infections. *Surg Clin N Am* 1988; 68: 199-213
19. Murinello A, Nunes G, Pernadas M^aC, Lamarão P, Almeida A, Soares A, et al. Fournier's gangrene. *Rev Gastrenterol Cirurg (in portuguese)* 1997; XIV: 49-60
20. Thwaini A, Khan A, Malik A, Cherian J, Barnz J, Sherill I, et al. Fournier's gangrene and its emergency management. *Postgrad Med J* 2006; 82: 516-519
21. Efem SE. Recent advances in the management of Fournier's gangrene: preliminary observations. *Surgery* 1993; 113: 200-204
22. Subrahmanyam M, Ugane SP. Honey dressing beneficial in treatment of Fournier's gangrene. *Ind J Surg* 2004; 65: 75-77
23. Tonks A, Cooper RA, Price AJ, Molan PC, Jones KP. Stimulation of TNF-2 release in monocytes by honey. *Cytokine* 2001; 14: 240-242
24. Laor E, Palmer LS, Tobia BM. Outcome prediction in patients with Fournier's gangrene. *J Urol* 1995; 154: 89-92
25. Corcoran AT, Smaldone MC, Gibbons EP, Walsh TJ, Davies BJ. Validation of the Fournier's gangrene severity index in a large contemporary series. *J Urol* 2008; 18: 944-998
26. Lin E, Yong S, Chin AW, Chow YC, Chen M, Lin WC, et al. Is Fournier's gangrene severity index useful for predicting outcome of Fournier's gangrene? *Urol Int* 2005; 75: 119-122